



PATIENT

Toby Gertz

SPECIES

Canine

BREED

Chihuahua

SEX

MI

AGE

2013

WEIGHT

7.4lbs

INTERPRETED BY

Maggie Machen Lamy,
DVM, DACVIM
(Cardiology)

PRESENTING CLINICAL SIGNS

History: Patient presented with a history of a grade 5/6 systolic murmur but most recently developed a cough that sounds “wheezy and hoarse” per o. On auscultation, grade 5-6/6 murmur noted with no crackles or wheezes noted in the chest. No cough on tracheal palpation. Serous discharge from the nares bilaterally. Began on Lasix and Pimobendan. Stable at home with no increase in respiratory rate. Radiographs revealed cardiomegaly and mild pulmonary edema from left sided congestive heart failure. Owner informed tenuous patient condition and stress of echo could cause complications and death, declined recommendations for cardiac referral/ER. Owner accepted risk.

Pertinent abnormal PE/Chem/CBC/UA Results: 3/21/22- CBC- mild monocytosis. Chem-hypocholesterolemia. T4 2.4 WNL.

Current medications: Lasix 12.5mg BID, Pimobendan 0.625mg BID, Gabapentin 75mg

Blood pressure: 5/6/22 on tail- 84, 110, 108, 108.

Sedation used: Not required to complete full diagnostic ultrasound.

Pertinent previous ultrasound results: No previous.

STAT: Requested by DVM.

Imaging performed by: Stephanie Pearce RDCS, RVT.

RADIOGRAPHIC FINDINGS *NOTE: Images submitted for supplemental information only.

5/6/22: Severe globoid cardiomegaly. Concern for impending CHF.

ECHOCARDIOGRAM FINDINGS

2D, m-mode, color flow and doppler imaging is available. The mitral valve is diffusely thickened with significant prolapse into the left atrial lumen. There is severe eccentric mitral regurgitation present. The MR velocity is normal. There is severe left atrial enlargement. There is mild left ventricular dilation. Left ventricular systolic function is hyperdynamic. No right atrial or ventricular dilation (subjective). Mild thickening of the tricuspid valve with mild TR. Velocity consistent with early PAH. There is normal systolic flow velocity across the aortic valve. The aortic valve appears trileaflet with normal mobility. The main pulmonary artery is normal in diameter. The pulmonic valve is normal in appearance. No pericardial/pleural effusion or cardiac masses are seen.

CARDIAC CHART

HOSPITAL NAME

Perry Hall AH

REFERRING VET

Dr. Breidenbaugh

INVOICE

24097

DATE

5/9/22

CANINE CARDIAC PARAMETERS	MR VMAX (m/s)	TR VMAX (m/s)	LA/AO (Boon method)	LA/AO (Heart Base; Swe)	FS (%)	EF (%)	EPSS (cm)
NORMAL PARAMETER	4.5-5.5	<2.7	1.3	<1.6	28-40	40-100	<0.6
PATIENT	5.4	2.9	NM	2.2	57	88	NM
CANINE CARDIAC PARAMETERS	HR (BPM)	AV VMAX (m/s)	PV MAX (m/s)	BODY WEIGHT (kg)	LA 2D short axis Base view (cm)	LVIDd Avg; 2D and m-mode short axis (cm)	LVIDs Avg; 2D and m-mode short axis (cm)
NORMAL PARAMETER	50-100	0.7-1.7	0.7-1.6	BELOW	BELOW	BELOW	BELOW
PATIENT	120	1.1	1.1	3.4	2.3	3.0	1.3
*Normal chamber parameters expressed as a mean value (SD)				3	1.27 (5.3)	2.46 (2.46)	1.36 (5.5)
BODY WEIGHT DEPENDENT PARAMETERS				5	1.40 (4.5)	2.74 (5.2)	1.60 (4.7)
<i>*Note: All measurements based upon multi-modal images and methods. An average value is reported.</i>				10	1.50 (3.8)	3.27 (3.5)	2.06 (3.1)
				15	1.83 (2.0)	3.71 (2.4)	2.43 (2.1)
				20	2.02 (1.9)	4.14 (2.2)	2.80 (2.0)

INTERPRETATION OF THE FINDINGS & FURTHER RECOMMENDATIONS

The cause of the murmur is chronic degenerative valve disease causing severe mitral and mild tricuspid regurgitation. Severe left atrial enlargement indicates the risk for spontaneous congestive heart failure is elevated. Early pulmonary hypertension is noted, which is likely secondary to chronic LA pressure elevation. No additional issues are identified.

In light of the clinical signs and severity of disease on echocardiogram, there is concern for early congestive heart failure. Continued medications are warranted lifelong as below. The dose of Lasix is quite high, and if the response has been positive a slight dose adjustment is advised. Monitoring of sleeping respiratory rates will be paramount to screen for congestive heart failure at home. Cough suppression to improve QOL can also be considered (hydrocodone, 0.2-0.4mg/kg up to q4-6h PRN) for any residual mechanical cough in the face of normal sleeping respiratory rates.

The average survival time of canine patients with active pulmonary edema is 8-9 months on medications; however, they generally are able to maintain a good quality of life for that period. Patient will always be at risk for recurrent CHF, development of arrhythmias/LA tear, syncope and/or sudden death in the future.

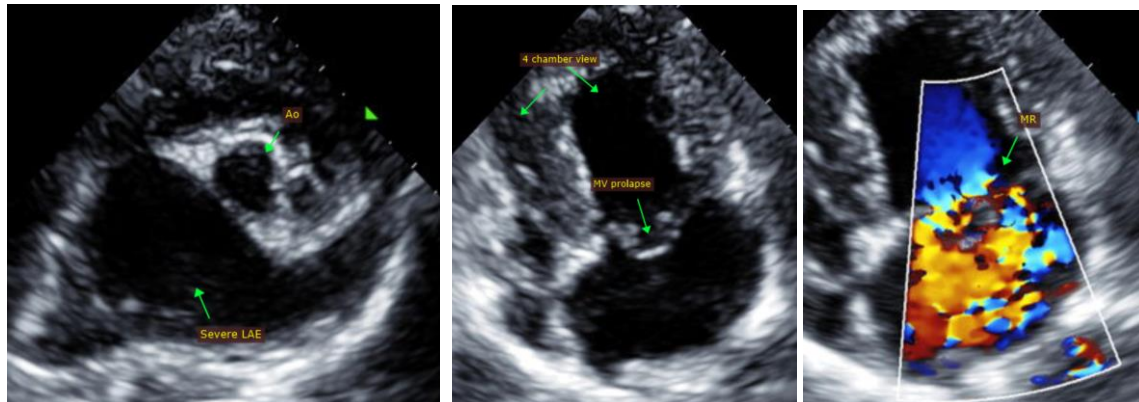
Omega fatty acid supplementation and mild salt restriction may also be of some long term benefit. Monitor for acute progression of the cough, labored breathing, exercise intolerance or collapse episodes in the future.

Plan: Institute Pimobendan 0.3mg/kg PO q12h. If respiratory signs have resolve, adjust dose to Furosemide 1-2mg/kg PO q12h. Institute spironolactone 1-2mg/kg PO q12h. If patient is or becomes unstable, highly recommend hospitalize for supportive care.

Monitor SRRs at home. Monitor renal values and BP in 10-14 days, then every 3-4 months while on diuretics. If doing well and BP >130mmHg, institute ACEI 0.5mg/kg PO q12h. Consider hydrocodone if needed for QOL.

Recommend conservative monitoring with a recheck echocardiogram in 6 months, sooner if any development of associated clinical signs occurs in the interim.

IMAGES



The information and recommendations provided are based on the images presented by the referring veterinarian. No evaluation can be communicated regarding pathology that was not visible in the image/video clips provided.

Thank you for this referral. This report was generated using transcription software, and minor dictation errors may be present. If the clinical or image interpretation does not parallel your findings or if I can be of any further assistance please contact me.

Maggie Machen Lamy, DVM
Diplomate of the American College of Veterinary Internal Medicine (Cardiology)
info@sonopath.com